

Newborn Critical Care Center (NCCC) Guidelines

Developmental Dysplasia of the Hip

BACKGROUND

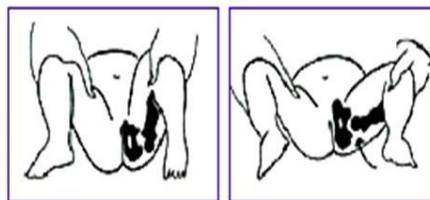
Developmental dysplasia of the hip (DDH) includes a range of hip abnormalities in which the femoral head and acetabulum are improperly aligned (i.e., dislocated, dislocatable or subluxated), leading to abnormal growth. DDH can lead to lifetime morbidity including gait abnormalities, pain and degenerative arthritis.

SCREENING

The goal of screening is to prevent a subluxated or dislocated hip by 6 to 12 months of age. The physical examination is the most important component of a DDH screening program, with imaging playing a secondary role. As such, all infants admitted to the NCCC should be screened for DDH by clinical hip exam.

Clinical Exam

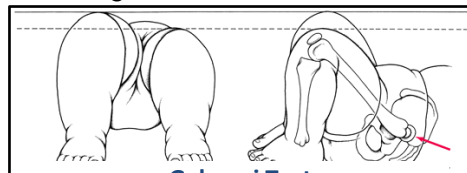
The Ortolani maneuver is the most important clinical test for detecting newborn hip dysplasia. To perform the Ortolani test, gently lift the flexed thigh and push the greater trochanter anteriorly (reducing dislocation). A positive sign is a distinctive 'clunk' which can be heard and felt as the femoral head relocates anteriorly into the acetabulum.



Ortolani Test

(Of note, the Barlow maneuver, in which the femoral head is adducted until it becomes subluxated or dislocated, has no proven predictive value for future hip dislocation. If it is performed, care should be taken to avoid any posterior-directed force during adduction, as it is possible that the maneuver itself could create hip instability.)

The Galeazzi test can be performed in infants < 3 months of age. Hips and knees are flexed at 90 degrees with feet flat. A positive test results in unequal femur lengths, with the femur appearing shorter on the dislocated side.



Galeazzi Test

At a minimum, clinical hip exams for infants in the NCCC should be performed shortly after birth and at the time of discharge. Additional, periodic exams may be performed according to clinical discretion. In addition to periodic

Ortolani tests, infants should be observed for limited or asymmetric hip abduction after the neonatal period.

All newborns with a positive Ortolani test or with limited or asymmetric hip abduction should have imaging obtained and then be referred to Pediatric Orthopedics.

Adjunctive Imaging

Most DDH occurs in children without risk factors. However, adjunctive imaging may be considered between 2 weeks and 6 months for high-risk male or female infants without positive physical exam findings. Risk factors include the following:

1. Breech presentation in the third trimester
2. Family history of DDH
3. Parental concern

4. Suspicious but inconclusive periodic examination
5. History of clinical hip instability
6. History of tight lower-extremity swaddling

Hip ultrasonography is the imaging modality of choice for infants between 2 weeks and 4 months. For infants 4-6 months of age at the time of screening, radiography (anteroposterior and frog pelvis views) can be considered as an alternative to ultrasonography. Radiography has a lower false-positive rate and is less expensive than ultrasonography, but exposes the newborn to radiation.

While one retrospective study in 2013 found a similar incidence of DDH in preterm and term infants with breech presentation, it is unclear whether this represents an important risk factor for infants born before 28 weeks gestation.

All newborns with an abnormal hip ultrasound or radiograph should be referred to Pediatric Orthopedics.

TREATMENT

Recommendations for treatment are based on clinical hip examination and imaging. Of note, infants with a stable clinical examination but abnormal imaging can be observed without bracing. A treatment plan should be determined by Pediatric Orthopedics.

PREVENTION

Recent research shows that babies whose legs are swaddled tightly with the hips and knees straight are at a notably higher risk for developing DDH.⁴ For healthy hip development, the legs should be able to bend up (flexion) and out (abduction) at the hips. This position allows for natural development of the hip joints.

References:

1. Shaw BA, Segal LS, AAP SECTION ON ORTHOPAEDICS. [Evaluation and Referral for Developmental Dysplasia of the Hip in Infants](#). *Pediatrics*. 2016;138(6):e20163107
2. Yang, Scott, Zusman, Natalie, Lieberman, Elizabeth, Goldstein, Rachel. Developmental Dysplasia of the Hip, *Pediatrics* (2019) 143 (1): e20181147.
3. Ahn, Leah, Souder, Chris. Developmental Dysplasia of the Hip. *OrthoBullets*. June 2022
4. Quan T, Kent AL, Carlisle H.J. Breech preterm infants are at risk for developmental dysplasia of the hip. *Paediatric Child Health* (2013). Aug; 49(8):658-63
5. [International Hip Dysplasia Institute](#)